ELSEVIER
SAUNDERS

Immunol Allergy Clin N Am
28 (2008) 277–291

IMMUNOLOGY
AND ALLERGY
CLINICS
OF NORTH AMERICA

The Hyper-IgE Syndromes

Alexandra F. Freeman, MD,
Steven M. Holland, MD*

Laboratory of Clinical Infectious Disease, National Institute of Allergy and Infectious Disease, Building 10, CRC B3-4141, MSC 1684, 9000 Rockville Pike, Bethesda, MD 20892-1684, USA

The hyper-IgE syndromes (HIES) are rare primary immune deficiencies characterized by elevated serum IgE, dermatitis, and recurrent skin and lung infections. There are two forms of HIES: a dominant form caused by mutations in *STAT3*, and a recessive form, for which a genetic cause is unclear [1–4]. These two different syndromes have distinct presentations, courses, and outcomes and share very little in terms of pathogenesis other than the IgE elevation. The dominant form is characterized by non-immunologic features including skeletal, connective tissue, and pulmonary abnormalities in addition to recurrent infections and eczema. In contrast, the recessive form lacks the somatic features and has marked viral infections and neurologic complications. This article discusses the diagnostic, laboratory, and clinical aspects of these disorders as well as their genetic etiologies.

Autosomal dominant hyper-IgE syndrome (*STAT3* deficiency)

The disease subsequently identified as HIES was described first as "Job's syndrome" by Davis and colleagues [5] in 1966, referring to the Biblical Job, who was "smote with sore boils." In 1972 the syndrome was refined by Buckley and colleagues [6], who recognized extremely high serum IgE levels. Since that time, the classic triad of eczema, recurrent skin and lung infections, and high serum IgE has been expanded to include skeletal, connective tissues, cardiac, and brain abnormalities [1,7,8]. Until 2007, HIES remained the

This project has been funded in whole or in part with federal funds from the National Cancer Institute, National Institutes of Health, under contract N01-CO-12400. The content of this publication does not necessarily reflect the views or policies of the Department of Health and Human Services, nor does mention of trade names, commercial products, or organizations imply endorsement by the United States Government.

* Corresponding author.
E-mail address: smh@nih.gov (S.M. Holland).

doi:10.1016/j.iac.2008.01.005 *immunology.theclinics.com*

last of the major immune deficiencies without either a known genetic etiology or a comprehensive understanding of the associated immune dysfunction. It now is known that *STAT3* mutations are responsible for most, if not all, cases of autosomal dominant HIES, and these mutations have begun to explain the multisystem nature of the disease [2,3]. To distinguish this dominant disease caused by *STAT3* mutation from the recessive forms of HIES and to distinguish this disease from other syndromes of IgE elevation, the authors also refer to this disease as "*STAT3* deficiency."

Clinical manifestations

STAT3 deficiency is a disease of multiorgan dysfunction (Box 1). Although eczema and recurrent infections usually bring patients to initial attention, these individuals have abnormalities in vessels, connective tissue, and skeleton. Before genetic testing, the diagnosis of HIES typically was difficult to confirm until both immunologic and somatic features appeared. A clinical scoring system has been developed that includes both of these categories [9].

Skin

A newborn rash usually is the first manifestation of *STAT3* deficiency [10,11]. Pustular and eczematoid rashes usually begin within the first month

Box 1. Clinical characteristics of *STAT3* deficiency

Immunologic characteristics (% frequency)
- Newborn rash (81%)
- Boils (87%)
- Recurrent pneumonias (87%)
- Pneumatocoeles (77%)
- Eczema (100%)
- Mucocutaneous candidiasis (83%)
- Peak serum IgE > 2000 IU/mL (97%)
- Eosinophilia (93%)
- Increased incidence of lymphoma

Non-immunologic characteristics (% frequency)
- Characteristic face (83%)
- Retained primary teeth (72%)
- Minimal trauma fractures (71%)
- Scoliosis > 10° (63%)
- Hyperextensibility (68%)
- Focal brain hyperintensities (70%)
- Chiari 1 malformations (18%)
- Craniosynostosis (unknown)
- Arterial aneurysms (unknown)

of life, typically first affecting the face and scalp. In a series of 43 patients, 8 babies (19%) were born with the rash, and 23 (53%) acquired the rash within the first week of life [10]. Biopsies typically show an eosinophilic infiltrate, and bacterial culture usually grows *Staphylococcus aureus*. The rash can be quite significant, especially in childhood. To achieve and maintain good control, antistaphylococcal therapies (antibiotics or topical antiseptics, such as bleach) often are essential.

Boils are a classic finding in this disease and are characteristic of the diagnosis. The degree of inflammatory symptoms, such as tenderness and warmth, often is quite variable. The "cold" abscesses initially described by Davis and colleagues [5] are common. Despite the absence of external signs of inflammation, there is frank pus upon aspiration, and *S aureus* usually is cultured. With prophylactic antibiotics, the occurrence of these boils typically diminishes substantially. Trouble areas may persist in intertriginous areas such as the axillae, the inguinal region, or under the breasts.

Lungs

Recurrent pyogenic pneumonias are the rule. Pneumonias typically start in childhood, and the most frequent bacteria isolates are *S aureus*, *Streptococcus pneumoniae*, and *Haemophilus influenzae* (Box 2). Similar to the occurrence of cold abscesses, these pneumonias may present with fewer symptoms (eg, cough, sputum production) than would be expected in a normal person given the extent of disease. This dearth of symptoms and subsequent delay in clinical presentation may contribute to advanced disease and significant tissue damage before identification and initiation of appropriate therapy. Pus is clearly present on sputum inspection or bronchoscopy.

Box 2. Pathogens of *STAT3* deficiency

Frequent pathogens
- *Staphylococcus aureus* (lung and skin)
- *Streptococcus pneumoniae* (lung)
- *Haemophilus influenzae* (lung)
- *Candida albicans* (mucocutaneous)

Secondary pathogens of lung
- *Pseudomonas aeruginosa*
- *Aspergillus* species
- *Scedosporium* species
- Nontuberculous mycobacteria

Less frequently seen pathogens
- *Pneumocystis jiroveci* (lung)
- *Histoplasma* species (gastrointestinal tract)
- *Cryptococcus* species (brain and gastrointestinal tract)

Although the pneumonias typically respond promptly to appropriate antimicrobial therapy, the healing of the lungs is aberrant. Pneumatocoeles and bronchiectasis form during the healing process and usually persist once the infection has cleared. These persistent structural abnormalities, which can be quite significant, predispose the patient to gram-negative bacterial infection (typically *Pseudomonas*) and fungal infections (typically *Aspergillus* or *Scedosporium* species) in addition to the primary pathogens in *STAT3* deficiency (Fig. 1). The secondary infections typically are indolent and difficult to clear. These long-term infections are more frequently associated with mortality than the acute pyogenic infections, causing rupture into large pulmonary vessels with life-threatening hemoptysis or fungal dissemination to the brain [12].

Other infections

Mucocutaneous candidiasis is common in *STAT3* deficiency, manifesting typically as oral thrush, vaginal candidiasis, or onychomycosis [1]. Systemic *Candida* infections are very rare and most likely are nosocomial in origin (eg, an indwelling catheter infection). Disseminated *Cryptococcus* and *Histoplasma* infections also occur, although less frequently than candidiasis. These uncommon yeast infections often are localized (eg, histoplasmosis of the tongue or intestinal cryptococcal infection) [13,14]. *Pneumocystis jiroveci* pneumonia also occurs, albeit infrequently, and its presentation in infants may be similar to the initial presentation of *Pneumocystis jiroveci* pneumonia in infants infected with HIV [15].

Musculoskeletal abnormalities

Skeletal abnormalities in *STAT3* deficiency include scoliosis, osteopenia, minimal trauma fractures, hyperextensibility, and degenerative joint disease. Scoliosis occurs in about 75% of patients, typically emerging during

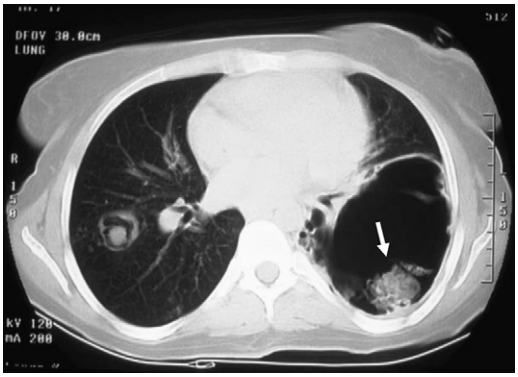

Fig. 1. Chest CT of an individual who has *STAT3* deficiency showing the characteristic pneumatoceles. The pneumatoceles are prone to infection with fungi and gram-negative bacteria. Arrow indicates an aspergilloma.

adolescence in a pattern similar to that of idiopathic scoliosis [1]. In some patients, there is associated leg length discrepancy; in others scoliosis develops or worsens after thoracotomy for lung infections. The scoliosis varies in severity, and some individuals have required surgical stabilization or correction.

Hyperextensibility of both the large and small joints is frequent and may be related to the early development of severe degenerative joint disease, particularly of the spine, that the authors have seen in several patients in their 20s to 40s. Several patients have required stabilization procedures as early as in their third decade, and many suffer from chronic pain caused by extensive arthritis. Minimal trauma fractures and decreased bone mineral density also are common but may occur independently of one another [1]. Fractures tend to be of the long bones, ribs, and pelvic bones. Bone resorption has been shown to be abnormally increased in patients who have HIES because of abnormalities in the prostaglandin synthetic pathway and is responsive to nonsteroidal agents [16,17]. Healing seems to be normal after surgery or fractures.

Cranial abnormalities

Craniosynostosis of varying degrees occurs but typically does not require surgical repair [18,19]. Chiari 1 malformations also occur fairly frequently; in one study of 50 individuals, 9 (18%) had Chiari 1 malformation on brain MRI [7]. The Chiari malformations observed typically do not require surgical repair and usually are incidental findings.

Dental abnormalities

Most individuals who have *STAT3* deficiency retain at least some, if not all, of their primary teeth past the age of normal primary dental exfoliation [1,20]. This manifestation seems to be a failure of the primary teeth to exfoliate, not of the secondary teeth to develop or to erupt. Once the primary teeth do exfoliate, whether by dental extraction or naturally, the secondary teeth, which are normally formed, emerge. At times, layers of both primary and secondary teeth are present simultaneously when the secondary teeth emerge although the primaries have not fallen out. There also are characteristic findings of the oral mucosa, tongue, roof of the mouth, and cheeks [21]. Central depressions in the tongue (central rhomboid glossitis) may be caused by or become secondarily infected with *Candida*. The palate typically has a high arch with varying degrees of a central band-type protrusion. Abnormally prominent wrinkles often are observed on the oral mucosa.

Vascular abnormalities

Arterial aneurysms are an important recently appreciated aspect of *STAT3* deficiency [8]. Bilateral berry aneurysms of the internal carotid arteries and mycotic aneurysm have been reported in an autopsy series of HIES [12]. A large aneurysm in the left anterior descending coronary artery

resulted in myocardial infarction in one adult male patient [8]. That case prompted the authors to look more closely at other adult patients who had HIES. The authors were surprised at the frequency of coronary artery anomalies, including arterial tortuosity, dilation, and aneurysms. Of 18 individuals studied by either cardiac CT or MRI, 14 had one of these abnormalities, with tortuosity and dilation predominating and aneurysms being present in only 4 patients (Freeman AF, Holland SM, Gharib A, unpublished data, 2008). Significant atherosclerosis is uncommon in the individuals studied by CT and MR angiography, despite these patients having risk factors for coronary artery disease. One of the patients had a myocardial infarction as the result of an aneurysm, clearly indicating that these findings can be medically important. Whether and when these aneurysms require therapy, and if so with what, is unclear. Whether the coronary and extracoronary aneurysms are reflections of the same underlying pathophysiology also remains to be determined.

Lacunar infarcts have been reported at a younger age than is typical and have had varying clinical consequences, ranging from thalamic infarction to no symptoms [7]. T2-weighted hyperintensities seen on brain MRI are similar to incidental findings that accumulate in otherwise healthy adults as they age but are seen at much younger ages than in the general population [7]. Similar hyperintensities in elderly, otherwise healthy, adults are thought to reflect small-vessel abnormalities, which may be signs of subtle vascular abnormalities, or demyelination. Gross neurologic abnormalities are not detected in the majority of patients with these findings.

Face

The characteristic facial appearance that individuals who have *STAT3* deficiency share may make patients resemble one another more than their family members [1,22,23]. Facial asymmetry, broad nose, and deep-set eyes with a prominent forehead are common. The facial skin has a rough appearance with exaggerated pore size. This characteristic appearance typically develops during childhood and adolescence.

Malignancies

An increased risk of malignancy is associated with *STAT3* deficiency [24–26]. Both Hodgkin's and non-Hodgkin's lymphoma have been described, with the majority of the non-Hodgkin's lymphomas being of B-cell origin with aggressive histology. Individuals have been treated successfully and apparently cured with chemotherapy. In one study of 11 individuals, 7 died, but 2 deaths were for reasons other than lymphoma [24]. The increased mortality may reflect a delay in diagnosis. Other cancers described in HIES include leukemia and cancers of the vulva, liver, and lung [26].

Laboratory abnormalities of STAT3 *deficiency*

The two most consistent laboratory findings of Job's syndrome are elevated serum IgE and eosinophilia; otherwise, there is a lack of pathognomic

laboratory signs. Therefore, the diagnosis historically has been more syndromic than laboratory based. The serum IgE typically peaks above 2000 IU/mL and usually is elevated even at the time of birth. It is important to keep in mind the natural change in IgE levels over time: they usually are undetectable in cord blood and rise to the adult range slowly over the years. In adulthood the IgE level may diminish over time in some individuals and actually can normalize, despite persistence of the clinical abnormalities of *STAT3* deficiency. (In one report, IgE levels normalized in 20% of patients) [1]. Eosinophilia almost always is present in these patients, at least at some point, but is not correlated with the serum IgE level.

Other laboratory findings are variable in *STAT3* deficiency. Total white blood cell counts typically are normal but may not increase appropriately during acute infection. Neutropenia has been reported but is uncommon. Serum IgG, IgA, and IgM typically are normal, although some individuals have deficiencies in one or more of these immunoglobulins.

Immunology of STAT3 *deficiency*

The mechanisms of the immune deficiencies in *STAT3* deficiency remain elusive. Multiple reports with small numbers of patients have conflicted regarding whether a neutrophil chemotactic defect is present and whether there is a T-helper 1/T-helper 2 cytokine imbalance [27–32].

STAT3 is a key regulator of many immunologic pathways. Mouse Stat3 homozygous knockouts die in utero, reflecting the absolute necessity of some Stat3 function for survival. Therefore, most experiments in mice have used organ-specific or conditional knockout animals. Animals with a myeloid-specific deletion of *Stat3* had increased expression of tumor necrosis factor-alpha (TNF-α) and interferon-gamma (IFN-γ) and decreased expression of interleukin (IL)-6 and IL-10 [33,34]. Consistent with these mouse data, microarray analysis of leukocytes from *STAT3*-deficient humans showed significant up-regulation of proinflammatory genes at rest or after stimulation [2]. Similarly, patients showed excessive proinflammatory cytokine production in response to innate immune agonists, consistent with the impaired regulation of these cytokines by *STAT3* [2]. After incubation with lipopolysaccharide, levels of TNF-α and IL-12 were elevated. IFN-γ also was increased after the mitogen phytohemagglutinin. As expected for a defect in *STAT3*, upon which the signaling of IL-6 and IL-10 depend, there are impaired responses to these cytokines. Monocyte chemoattractant protein-1 levels are diminished after IL-6 stimulation of leukocytes from patients who have HIES [2].

Many of the specific immune defects of *STAT3* deficiency remain somewhat unexplained. Infections of the lung and skin may predominate because *STAT3* is a key regulator of beta-defensins of the skin and lung through IL-22 signaling [35]. The high IgE may result from defects in *STAT3*-mediated IL-21 receptor signaling, because heterozygous IL-21 receptor knockout

mice have increased IgE [36]. HIES is not exclusively a disorder of too little inflammation and resulting inability to control invading micro-organisms. It is also, surprisingly, a disorder of too much inflammation. The increased inflammation is evident in the lung, where tissue breakdown leading to pneumatocoeles may be a consequence of exuberant inflammation. In contrast, there are aspects of *STAT3* deficiency that are more consistent with too little inflammation, such as the frequent "cold" abscesses and the relative paucity of symptoms compared with the extent of disease. Exploration and charting of these areas of aberrant regulation, both too little and too much, should be highly informative about the nature of the early and late aspects of inflammation.

Genetics of STAT3 *deficiency*

STAT3 mutations cause most, if not all, cases of autosomal dominant HIES. So far, mutations have been found in only two regions of the *STAT3* gene: the SH2 domain (mediating protein–protein interaction) and the DNA-binding domain (mediating the interaction of protein with DNA). There are mutational hot spots in both the SH2 and DNA-binding domains, as shown by multiple independent families carrying the same mutation [2,3]. Many of the same mutations have been found in multiple ethnic groups among whites, Africans, and Asians, indicating recurrent de novo mutations. All mutations found thus far have been missense mutations or in-frame deletions, allowing the production of full-length mutant STAT3 protein able to exert a dominant negative effect. The importance of the production of mutant protein with dominant negative effect is shown by the fact that mice with heterozygous deletions of Stat3 have no apparent phenotype, suggesting that having a single copy of a functional gene is adequate for most functions. This finding suggests that the development of human HIES requires an inhibition of function below that afforded by a single allele. The mutations have no intrinsic function on their own but act in a dominant-negative manner to inhibit the function of the normal allele [3]. Consistent with this in vitro phenotype, HIES is transmitted in an autosomal dominant manner. Importantly, somatic mosaicism has been recognized in a man who had an intermediate HIES score but had two HIES-affected children. His peripheral blood showed evidence for two populations of cells: one population with the mutant allele, and one population without it [2]. Efforts to define the existence of somatic mutations that cause intermediate types of disease are underway. Despite the existence of only two mutated domains of *STAT3* that are thought to mediate such different effects as DNA and protein binding, genotype/phenotype correlations have yet to be determined.

STAT3 is a major signal transduction protein involved in diverse pathways including wound healing, angiogenesis, immune pathways, and cancer. Homozygous *STAT3* knockout mice are not viable, but organ- and

tissue-specific knockouts are and have been informative. In mice with *STAT3* deficiency of the pulmonary epithelium, there is excessive inflammation and airspace enlargement when exposed to hyperoxia, reminiscent of the pneumatoceles that form following bacterial pneumonia in patients who have HIES [37]. Mice with hematopoiesis-specific *STAT3* deficiency develop osteopenia and increased osteoclast generation, reminiscent of the osteopenia and fractures of HIES patients [38]. Mice with brain-specific *STAT3* have increased inflammation, demyelination, and astrocytosis, reminiscent of the hyperintensities seen in brain MRIs of patients who have HIES [7,39]. *STAT3* also is involved in vascular remodeling and atherosclerosis, which may be relevant to the coronary artery aneurysms and lack of atherosclerosis in patients who have HIES [40].

Therapy of hyper-IgE syndromes

Only now are specific therapies for *STAT3* deficiency being developed, but successful supportive care has been well honed. Effective skin care often depends on control of both superficial and invasive *S aureus* infection. Bleach baths (120 mL bleach in a tub of water, soaked in for 15 minutes three times weekly) and swimming in chlorinated pools are highly effective. Systemic immune suppression (eg, with corticosteroids) to treat the eczema usually is not necessary, because there typically is an excellent response to antimicrobials, but topical steroids help in difficult cases. Antimicrobial prophylaxis to prevent *S aureus* skin and lung infection (eg, 2.5 mg/kg of the trimethoprim component twice daily) may be broadened if gram-negative lung infections occur. Antifungal prophylaxis to prevent pulmonary aspergillosis remains attractive but unproven, but it is highly effective in treating and preventing mucocutaneous candidiasis. Ideally, treatment of pneumonia is guided by the etiologic agent. Bronchoscopy is helpful to recover the pathogen and to assist with clearance of mucus and pus, because these patients often do not have an adequate cough response. Because *STAT3*-deficient patients often feel well and have minimal fever despite significant infection, it is good to have a low threshold for investigating slight changes, such as new cough, chest discomfort, or fatigue, even in the absence of fever. The decision to resect the large pneumatoceles that sometimes form following pneumonia is complex. These large cysts may become secondarily infected and be a source of infection, bleeding, and possibly death. On the other hand, thoracic surgery can be complicated by poor expansion of the remaining lung after surgery, often resulting in thoracoplasty.

Before *STAT3* deficiency was identified as the cause of HIES, there were only a few immunomodulator trials. Levamisole is an unusual antihelminthic drug that also stimulates T-cell and natural killer–cell function. In a blinded, randomized study, however, levamisole was found to be inferior to placebo [41]. IFN-γ has been used with mixed results. In vitro it improved neutrophil chemotaxis, but in vivo it had inconsistent effects on IgE levels

[42]. Intravenous immunoglobulin may decrease the number of infections for some patients [43]. Case reports and small case series have extolled cyclosporine and histamine-2 receptor blockade [44,45]. Omalizumab (the monoclonal antibody against IgE) has not yet been studied, and it is unclear whether there may be any benefit.

Two bone marrow transplantations in HIES patients have been reported [46,47]. An adult died 6 months after transplantation [47]. His death was thought to have been caused by complications of the transplantation, but his serum IgE level decreased and his improvement in HIES-related symptoms in the posttransplantation interval. A 7-year-old girl underwent transplantation because of severe HIES. Although she initially had a good response, when posttransplant immune suppression was weaned, her serum IgE once again became elevated, and infections recurred despite engraftment of the donor cells [46]. Subsequently she seems to be doing well, leaving open issues of short- and long-term benefits of transplantation (A. Cant, personal communication, 2007).

The role of bisphosphonates in treating the osteoporosis and minimal-trauma fractures is undefined. Although the authors have treated several patients with bisphosphonates leading to improved bone mineral density without adverse events, it is unclear whether this improvement will translate into fewer fractures. Possible adverse dental events from bisphosphonates also remain unclear. The proper therapy for coronary artery aneurysms or other blood vessel abnormalities, if any, is undefined. Coronary artery aneurysms from Kawasaki disease typically are treated with anticoagulation depending on the size of aneurysm (from aspirin to warfarin). The development, progression, and significance of the arterial abnormalities in *STAT3* deficiency are unknown, however. The hypothetical benefits of anticoagulation must be weighed against the real risks of pulmonary hemorrhage. Close attention to blood pressure and other cardiovascular risk factors seems sensible.

A complex multisystem disease like *STAT3* deficiency requires a sophisticated multidisciplinary approach. In addition to close management of infectious disease, other subspecialists often are required. The orchestrated expertise of orthopedists for scoliosis, fractures, and degenerative joints; dentists to address the retained primary teeth; and pulmonologists for diagnostic and therapeutic bronchoscopy and pulmonary toilet is necessary.

Autosomal recessive hyper-IgE syndrome

In 2004, Renner and colleagues [4] described 13 patients from six consanguineous families who had a disease similar to, but distinct from, what now is known to be autosomal dominant HIES (*STAT3* deficiency). Their patients had elevated serum IgE, eczema, and recurrent skin and cutaneous viral infections but lacked the connective tissue and skeletal findings characteristic of *STAT3* deficiency. One patient has been described as having

a recessive disease similar to autosomal recessive (AR)-HIES caused by a homozygous mutation in tyrosine kinase 2 (*Tyk2*), a major signal-transducing molecule for IL-12, IL-6, and IFN-α [48]. *Tyk2* deficiency, however, is distinct from AR-HIES, and patients who have AR-HIES have normal *Tyk2* and *STAT3* sequences [49].

Clinical manifestations

The predominant clinical manifestations of AR-HIES are severe eczema and recurrent skin and lung infections (Box 3) [4]. All of the patients described as having AR-HIES have had severe eczematoid rashes, starting early in life, although not necessarily in the newborn period. Skin abscesses do occur, typically caused by *S aureus*. The skin disease of AR-HIES differs from *STAT3* deficiency in the much higher incidence of cutaneous viral infections, including Molluscum contagiosum, herpes simplex, and varicella zoster virus infections. Patients who have AR-HIES and those who have *STAT3* deficiency share the propensity for developing mucocutaneous candidiasis. Sinopulmonary infections are common in AR-HIES; causative agents include *S aureus*, *H influenzae*, *Proteus mirabilis*, *P aeruginosa*, and *Cryptococcus*. Unlike *STAT3*-deficient patients, in whom pneumatoceles complicate pneumonias, patients who have AR-HIES heal their lung infections without pneumatoceles. Fatal sepsis occurs in AR-HIES from both gram-positive and gram-negative bacteria.

Patients who have AR-HIES have more symptomatic neurologic disease than those who have *STAT3* deficiency [4]. In the Renner series [4], seven patients had neurologic symptoms, ranging from facial paralysis to hemiplegia. The etiology of the neurologic complications was not clear for all patients, but one had a cerebral cryptococcoma with meningitis, and others had severe central nervous system vasculitis.

Box 3. Clinical characteristics of autosomal recessive hyper-IgE syndrome

Eczema
Boils
Recurrent pneumonia without pneumatoceles
Sepsis
Mucocutaneous candidiasis
Skin viral infections
Neurologic symptoms
Vasculitis
Increased serum IgE
Eosinophilia

AR-HIES lacks the connective tissue and skeletal abnormalities of *STAT3* deficiency. Patients who have AR-HIES have normal primary tooth exfoliation, no tendency for mild-trauma fractures, and normal facies.

Immunologic manifestations

Patients who have AR-HIES have high serum IgE levels, comparable to those who have *STAT3* deficiency [4]. Their eosinophilia typically is higher than in *STAT3* deficiency. Autoimmune phenomena, including hemolytic anemia, may occur. Lymphocyte phenotyping and function are inconsistent in AR-HIES, although decreased lymphocyte proliferation was seen in response to a staphylococcal antigen. Neutrophil chemotaxis and nitrobluetetrazolium reduction are normal.

Genetics of autosomal recessive hyper-IgE syndrome

The patients who had AR-HIES and *Tyk2* deficiency were products of consanguineous unions [4,48]. The *Tyk2*-deficient patient shares features of AR-HIES including high serum IgE levels, eczematoid rash, and recurrent skin and sinopulmonary bacterial and viral infections. He had Bacille Calmette-Guerin and salmonella infections, however, which are seen more commonly in defects of the IFN-γ/IL-12 axis. Indeed, upon cytokine stimulation of the peripheral blood mononuclear cells, defects were found in IL-12 and IFN-α signaling. This *Tyk2*-deficient patient had a homozygous mutation leading to a four-nucleotide deletion and resulting in a premature stop codon. His related parents were heterozygous for the same deletion and were healthy.

Mutations of *Tyk2* are absent in AR-HIES [48]. Therefore, although it is possible that *Tyk2* mutations may cause some cases of AR-HIES disease, AR-HIES probably is heterogeneous, with more than one gene contributing to its etiology. Because *STAT3* is the genetic deficiency in autosomal dominant HIES, related genes in these pathways may cause some of these undefined diseases.

Therapy of autosomal recessive hyper-IgE syndrome

Therapy of AR-HIES remains supportive and has been less explored than therapy for *STAT3* deficiency. Prophylactic antimicrobials probably help, with antistaphylococcal agents, antivirals if needed, and antifungals if mucocutaneous candidiasis or invasive fungal disease occurs. Aggressive skin care may help prevent invasive bacterial infection.

Disease in AR-HIES often is more severe than in *STAT3* deficiency. Immunomodulatory therapies and bone marrow transplantation need further exploration.

Summary

Hyper-IgE syndromes were described first in 1966 and until recently remained one of the few primary immunodeficiencies without a genetic etiology. Now, however, two genetic defects have been described: *STAT3* mutations act in a dominant negative manner to cause of autosomal dominant HIES, and *Tyk2* deficiency acted in a recessive manner to cause one of the cases of AR-HIES. Investigators now need to focus on understanding the pathogenesis of these complicated diseases. Understanding how *STAT3* deficiency leads to the many facets of this disease may help investigators understand diseases that are more common, such as idiopathic scoliosis, atopic dermatitis, staphylococcal skin abscesses, and the coronary artery aneurysms of Kawasaki disease. Understanding the pathogenesis of *STAT3* deficiency will make it possible to create better therapies to prevent the morbidity and mortality of many diseases, including *STAT3* deficiency.

References

[1] Grimbacher B, Holland SM, Gallin JI, et al. Hyper-IgE syndrome with recurrent infections-an autosomal dominant multisystem disorder. N Engl J Med 1999;340:692–702.
[2] Holland SM, DeLeo FR, Elloumi HZ, et al. *STAT3* mutations in the hyper-IgE syndrome. N Engl J Med 2007;18:1608–19.
[3] Minegishi Y, Saito M, Tsuchiya S, et al. Dominant negative mutations in the DNA-binding domain of *STAT3* cause hyper-IgE syndrome. Nature 2007;448:1058–62.
[4] Renner ED, Puck JM, Holland SM, et al. Autosomal recessive hyperimmunoglobulin E syndrome: a distinct disease entity. J Pediatr 2004;144:93–9.
[5] Davis SD, Scaller SJ, Wedgwood RJ. Job's syndrome: recurrent, "cold", staphylococcal abscesses. Lancet 1966;1:1013–5.
[6] Buckley RH, Wray BB, Belmaker EZ. Extreme hyperimmunoglobulinemia E and undue susceptibility to infection. Pediatrics 1972;49:59–70.
[7] Freeman AF, Collura-Burke CJ, Patronas NJ, et al. Brain abnormalities in patients with hyperimmunoglobulin E syndrome. Pediatrics 2007;119:e1121–5.
[8] Ling JC, Freeman AF, Gharib AM, et al. Coronary artery aneurysms in patients with hyper IgE recurrent infection syndrome. Clin Immunol 2007;122:255–8.
[9] Grimbacher B, Schaffer AA, Holland SM, et al. Genetic linkage of hyper-IgE syndrome to chromosome 4. Am J Hum Genet 1999;65:735–44.
[10] Chamlin SL, McCalmont TH, Cunningham BB, et al. Cutaneous manifestations of hyper-IgE syndrome in infants and children. J Pediatr 2002;141:572–5.
[11] Eberting CL, Davis J, Puck JM, et al. Dermatitis and the newborn rash of hyper-IgE syndrome. Arch Dermatol 2004;140:1119–25.
[12] Freeman AF, Kleiner DE, Nadiminti H, et al. Causes of death in hyper-IgE syndrome. J Allergy Clin Immunol 2007;119:1234–40.
[13] Hutto JO, Bryan CS, Greene FL, et al. Cryptococcosis of the colon resembling Crohn's disease in a patient with the hyperimmunoglobulinemia E syndrome. Gastroenterology 1988;94:808–12.
[14] Jacobs DH, Macher AM, Handler R, et al. Esophageal cryptococcosis in a patient with the hyperimmunoglobulin E-recurrent infection (Job's) syndrome. Gastroenterology 1984;87:201–3.
[15] Freeman AF, Davis J, Anderson VL, et al. *Pneumocystis jiroveci* infection in patients with hyper-immunoglobulin E syndrome. Pediatrics 2006;118:e1271–5.

[16] Cohen-Solal M, Prieur AM, Prin L, et al. Cytokine-mediated bone resorption in patients with the hyperimmunoglobulin E syndrome. Clin Immunol Immunopathol 1995;76:75–81.
[17] Leung DY, Key L, Steinberg JJ, et al. Increased in vitro bone resorption by monocytes in the hyper-immunoglobulin E syndrome. J Immunol 1988;140:84–8.
[18] Hoger PH, Boltshauser E, Hitzig WH. Craniosynostosis in hyper-IgE syndrome. Eur J Pediatr 1985;144:414–7.
[19] Smithwick EM, Finelt M, Pahwa S, et al. Cranial synostosis in Job's syndrome. Lancet 1978; 15:826.
[20] O'Connell AC, Puck JM, Grimbacher B, et al. Delayed eruption of permanent teeth in hyperimmunoglobulinemia E recurrent infection syndrome. Oral Surg Oral Med Oral Pathol Oral Radiol Endod 2000;89:177–85.
[21] Domingo D, Freeman AF, Davis J, et al. Novel intraoral phenotypes in hyper immunoglobulin E syndrome. Oral Dis 2007;14:1–9.
[22] Buckley RH. The hyper-IgE syndrome. Clin Rev Allergy Immunol 2001;20:139–54.
[23] Borges WG, Hensley T, Carey JC, et al. The face of Job. J Pediatr 1998;133:303–5.
[24] Leonard GD, Posadas E, Herrmann PC, et al. Non-Hodgkin's lymphoma in Job's syndrome: a case report and review of the literature. Leuk Lymphoma 2004;45:2521–5.
[25] Gorin LJ, Jeha SC, Sullivan MP, et al. Burkitt's lymphoma developing in a 7 year old boy with hyper IgE syndrome. J Allergy Clin Immunol 1989;83:5–10.
[26] Oztop I, Demirkan B, Tarhan O, et al. The development of a pulmonary adenocarcinoma in a patient with Job's syndrome, a rare immunodeficiency condition. Tumori 2004;90:132–5.
[27] Borges WG, Augustine NH, Hill HR. Defective interleukin-12/interferon-gamma pathway in patients with hyperimmunoglobulinemia E syndrome. J Pediatr 2000;136:176–80.
[28] Chehimi J, Elder M, Greene J, et al. Cytokine and chemokine dysregulation in hyper-IgE syndrome. Clin Immunol 2001;100:49–56.
[29] Del Prete G, Tiri A, Maggi E, et al. Defective in vitro production of gamma-interferon and tumor necrosis factor-alpha by circulating T cells from patients with the hyper-immunoglobulin E syndrome. J Clin Invest 1989;84:1830–5.
[30] Donabedian H, Gallin JI. The hyperimmunoglobulin E recurrent-infection (Job's) syndrome. A review of the NIH experience and the literature. Medicine (Baltimore) 1983; 62:195–208.
[31] Hill HR, Ochs HD, Quie PG, et al. Defect in neutrophil granulocyte chemotaxis in Job's syndrome of recurrent "cold" staphylococcal abscesses. Lancet 1974;14:617–9.
[32] Rodriguez MF, Patino PJ, Montoya F, et al. Interleukin 4 and interferon-gamma secretion by antigen and mitogen-stimulated mononuclear cells in the hyper-IgE syndrome: no Th-2 cytokine pattern. Ann Allergy Asthma Immunol 1998;81:443–7.
[33] Murray PJ. The JAK-STAT signaling pathway: input and output integration. J Immunol 2007;178:2623–9.
[34] Welte T, Zhang SSM, Wang T, et al. *STAT3* deletion during hematopoiesis causes Crohn's disease-like pathogenesis and lethality: a critical role of *STAT3* in innate immunity. Proc Natl Acad Sci U S A 2003;100:1879–84.
[35] Wolk K, Kunz S, Witte E, et al. IL-22 increases the innate immunity of tissues. Immunity 2004;21:241–54.
[36] Ozaki K, Spolski R, Feng CG, et al. A critical role for IL-21 in regulating immunoglobulin production. Science 2002;298:1630–4.
[37] Hokuto I, Ikegami M, Yoshida M, et al. Stat-3 is required for pulmonary homeostasis during hypoxia. J Clin Invest 2004;113:28–37.
[38] Zhang Z, Welte T, Troiano N, et al. Osteoporosis with increased osteoclastogenesis in hematopoietic cell-specific *STAT3*-deficienct mice. Biochem Biophys Res Commun 2005;328: 800–7.
[39] Okada S, Nakamura M, Katoh H, et al. Conditional ablation of Stat3 or Socs3 discloses a dual role for reactive astrocytes after spinal cord injury. Nat Med 2006;12:829–34.

[40] Wincewicz A, Sulkowska M, Rutkowski R, et al. *STAT1* and *STAT3* as intracellular regulators of vascular remodeling. Eur J Intern Med 2007;18:267–71.
[41] Donabedian H, Alling DW, Gallin JI. Levamisole is inferior to placebo in the hyperimmunoglobulin E recurrent-infection (Job's) syndrome. N Engl J Med 1982;307:290–2.
[42] King CL, Gallin JI, Malech HL, et al. Regulation of immunoglobulin production in hyperimmunoglobulin E recurrent-infection syndrome by IFN-gama. Proc Natl Acad Sci U S A 1989;86:10085–9.
[43] Kimata H. High dose intravenous gammaglobulin treatment for hyperimmunoglobulinemia E syndrome. J Allergy Clin Immunol 1995;95:771–4.
[44] Etzioni A, Shehadeh N, Brecher A, et al. Cyclosporin A in hyperimmunoglobulin E syndrome. Ann Allergy Asthma Immunol 1997;78:413–4.
[45] Thompson RA, Kumararatne DS. Hyper-IgE syndrome and H2 receptor blockade. Lancet 1989;2:630.
[46] Gennery AR, Flood TJ, Abinun M, et al. Bone marrow transplantation does not correct the hyper IgE syndrome. Bone Marrow Transplant 2000;25:1303–5.
[47] Nester TA, Wagnon AH, Reilly WE, et al. Effects of allogeneic peripheral stem cell transplantation in a patient with Job syndrome of hyperimmunoglobulinemia E and recurrent infections. Am J Med 1998;105:162–4.
[48] Minegishi Y, Saito M, Morio T, et al. Human tyrosine kinase 2 deficiency reveals its requisite roles in multiple cytokine signals involved in innate and acquired immunity. Immunity 2006; 25:745–55.
[49] Woellner C, Schaffer AA, Puck JM, et al. The hyper IgE syndrome and mutations in Tyk2. Immunity 2007;26:535.