

## Familial Spastic Paraplegia as the Presenting Manifestation in Patients With Purine Nucleoside Phosphorylase Deficiency

### ABSTRACT

We report two siblings with purine nucleoside phosphorylase deficiency revealed by isolated spastic paraplegia, whereas symptoms of immune deficiency did not become apparent until 3 years of age. As the concurrence of immunodeficiency and neurologic problems strongly suggests the diagnosis of purine nucleoside phosphorylase deficiency, special attention should be paid to counts of lymphocytes in any infant with spastic paraplegia. (*J Child Neurol* 2003;18:140-141).

Purine nucleoside phosphorylase deficiency is a rare autosomal recessive disorder accounting for 4% of patients with severe combined immunodeficiency.<sup>1</sup> Typically, patients with purine nucleoside phosphorylase deficiency have recurrent infections, usually beginning in the first year of life, associated with neurologic disorders, malignancies, and autoimmune conditions.<sup>1</sup> Various neurologic complications are possible, such as spasticity, developmental delay, and cerebrovascular diseases.<sup>1-10</sup> In this first report of Tunisian siblings with purine nucleoside phosphorylase deficiency, the disease revealed isolated spastic paraplegia, whereas symptoms of immune deficiency did not become apparent until 3 years of age.

### Case Reports

The first patient, a girl, born in 1998, was the second child of consanguineous Tunisian parents. A sister had developed progressive spastic paraplegia from the first year of life. Cognitive development was normal. At 3 years of age, magnetic resonance imaging (MRI) of the brain showed abnormal hypersignals in the white matter located behind the occipital horns and in the centrum semiovale (Figure 1). Uric acidemia was normal (18.4  $\mu\text{mol/dL}$ ). From 3 years of age, she complained of recurrent respiratory infections. She died at 4 years, 8 months from malignant lymphoma of the B-immunoblastic type.

The second patient was born after an uncomplicated gestation and delivery. She was first referred at 6 months of age for mild generalized hypotonia. At 1 year, she was unable to sit, and physical examination showed spastic paraplegia with positive Babinski and Rossolimo reflexes, contrasting with decreased tendon reflexes in lower limbs. At 4 years of age, she did not show any progress in motor milestones, whereas intellectual performances were relatively spared. Ophthalmic examination was normal. From 3 years of age, she developed repeated chest infections.

MRI of the brain and spine was normal at 8 months and at 20 months of age. Motor nerve stimulations at 20 months exhibited reduction in conduction velocity (21 to 33 m/second) and conduction blocks, whereas sensory nerve potentials could not be elicited. Nine months later, electromyographic studies showed an obvious improvement of nerve conduction velocities. Electroencephalogram and auditory and visual evoked potentials were normal, but sensorial ones were absent bilaterally. Cerebrospinal fluid contained 55 mg/dL of protein (normal = 20-40). Blood lactates, pyruvates, amino acids, and  $\alpha$ -fetoprotein were at normal amounts. Uric acid level in the serum was low: 10  $\mu\text{mol/dL}$  (normal = 17.9-41.6). Epstein-Barr virus antibodies were absent both in blood and cerebrospinal fluid. Human immunodeficiency virus and human T-lymphotropic virus

type I were not found in the child and her mother. Further investigations confirmed the diagnosis of purine nucleoside phosphorylase deficiency: decreased lymphocyte counts, decreased lymphocytes, proliferative response to mitogens, and absence of any purine nucleoside phosphorylase activity in erythrocytes and lymphocytes. The levels of immunoglobulins were normal. Adenosine desaminase and S-adenosylhomocysteine hydrolase activities were normal in lymphocytes. Molecular analysis revealed a homozygous missense mutation at GCA $\rightarrow$ ACA (Ala 117-Thr). At present, she is awaiting bone marrow transplantation.

### Discussion

These two siblings have purine nucleoside phosphorylase deficiency with predominant central nervous system involvement. In both patients, the neurologic symptoms remained isolated for a long time as recurrent infections did not develop until the third year of life despite severe combined immunodeficiency. Thus, the clinical presentation could be misleading for spastic diplegic cerebral palsy or familial spastic paraplegia. On the other hand, severe neurologic manifestations associated with hypouricemia can suggest other conditions, such as molybdenum cofactor deficiency and phosphoribosyl pyrophosphate synthetase deficiency.

The neurologic complications, which have been reported in more than half of purine nucleoside phosphorylase-deficient children,<sup>1-10</sup> equate well with the severity of the enzyme deficiency.<sup>2</sup> They include spastic diplegia or tetraparesis, choreoathetosis, retarded motor development, ataxia, hypotonia, behavioral difficulties, and varying degrees of mental retardation.<sup>1-10</sup> Stroke may also occur, as reported in a 13-year-old girl who presented with repeated hemiparesis.<sup>3</sup> The neurologic disease was present prior to the immunodeficiency state in at least 7 of 35 patients with purine nucleoside phosphorylase deficiency.<sup>1-3</sup> It is noteworthy that our patient showed a transient peripheral neuropathy, which is not common in patients with purine nucleoside phosphorylase deficiency. This finding could suggest a postinfectious demyelinating process compatible with Guillain-Barré syndrome, as reported by Tam and Leshner in their patient, following varicella.<sup>3</sup> The sister of our patient showed bilateral white-matter changes involving the centrum semiovale. Such abnormalities, which have not been reported to date in purine nucleoside phosphorylase deficiency, coincide with the predominance of pyramidal signs in the neurologic presentation, but their interpretation is not clear. Vascular abnormalities have been reported in association with purine nucleoside phosphorylase deficiency,<sup>3</sup> thus, white-matter degenerative changes might be the result of a chronic vascular impairment.

Many metabolic mechanisms have been proposed to suggest a toxic effect in purine nucleoside phosphorylase deficiency.<sup>1-3</sup> Depletion of deoxyguanosine triphosphate has been proposed to correlate with neurologic deficits. Besides the role of purine nucleosides and purine nucleotides phosphates in modulating central nervous system functions and neurotransmission, it has been postulated that low levels of purine nucleoside phosphorylase in endothelial cells create a chronic endothelial damage. In addition, an autoimmune process, which has been observed in one third of cases of purine nucleoside phosphorylase deficiency, could play a role in the pathogenesis of the vasculopathy.<sup>1-3</sup>

The human *PNP* gene has been mapped to chromosome 14q13. Various mutations included missense mutations, microdeletions,

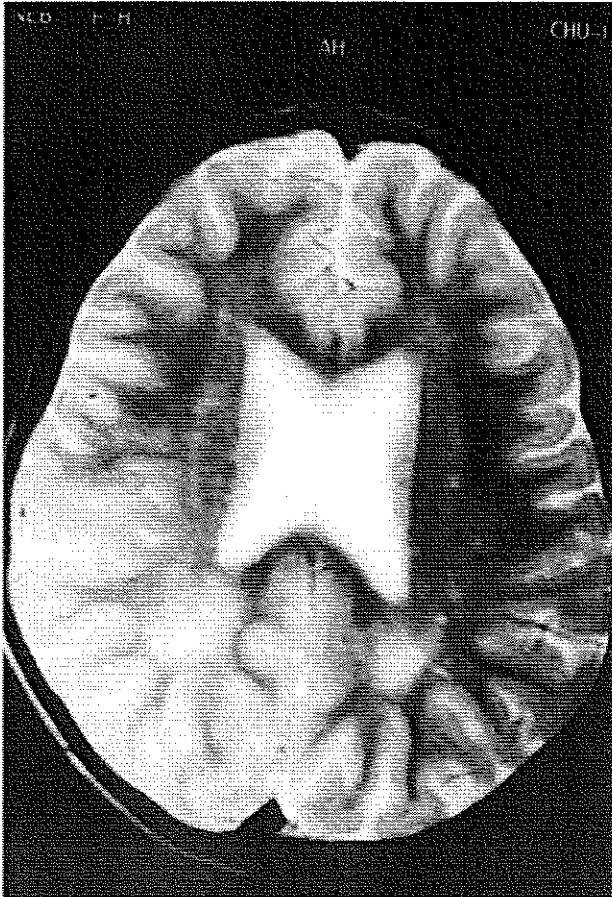


Figure 1. T<sub>2</sub>-weighted magnetic resonance image of the older child showing abnormal hypersignals in the white matter located behind the occipital horns.

and point mutations affecting splicing.<sup>11</sup> The ala 117-Thr missense mutation identified in our patient is novel. There is no clear correlation between genotypes and clinical phenotypes, especially as regards the neurologic complications.

The only current therapy of purine nucleoside phosphorylase deficiency is bone marrow transplantation. As suggested by the 10 patients with purine nucleoside phosphorylase deficiency who have undergone bone marrow transplantation, the central nervous system injury could have been prevented but is not reversible.<sup>4,12</sup>

In conclusion, purine nucleoside phosphorylase deficiency may have spastic paraplegia as the only presenting symptom. As the concurrence of immunodeficiency and neurologic problems strongly suggests the diagnosis, special attention to the serum uric acid level and lymphocyte counts should be paid in any infant with spastic paraplegia or other unexplained progressive neurologic disease.

### Acknowledgments

We thank the following doctors involved in the investigation of this family: P. Kamoun (Paris, France) and C. Roifman (Toronto, Canada).

Brahim Tabarki, MD  
 Moncef Yacoub, MD  
*Service de Pédiatrie*  
*Hôpital Farhat Hached*  
 Kalthoum Tlili, MD  
*Service de Radiologie*  
*Hôpital Sahloul*  
 Anouar Trabelsi, MD  
 Mohamed Dogui, MD  
*Service de Neurophysiologie*  
*Hôpital Sahloul*  
 Ahmed S. Essoussi, MD  
*Service de Pédiatrie*  
*Hôpital Farhat Hached*  
 Sousse, Tunisia

Received Oct 24, 2002. Received revised Dec 2, 2002. Accepted for publication Dec 3, 2002.

Address correspondence to Dr Brahim Tabarki, Service de Pédiatrie, Hôpital Farhat Hached, avenue ibn el jazzar, 4000 Sousse, Tunisia. Tel: 216-73223311; fax: 216-73226702; e-mail: brahim.mlaiki@ms.tn.

### References

1. Markert ML: Purine nucleoside phosphorylase deficiency. *Immunodef Rev* 1991;3:45-81.
2. Simmonds HA, Fairbanks LD, Morris GS, et al: Central nervous system dysfunction and erythrocyte guanosine triphosphate depletion in purine nucleoside phosphorylase deficiency. *Arch Dis Child* 1987;62:385-391.
3. Tam DA, Leshner RT: Stroke in purine nucleoside phosphorylase deficiency. *Pediatr Neurol* 1995;12:146-148.
4. Baguette C, Vermeylen C, Brichard B, et al: Persistent developmental delay despite successful bone marrow transplantation for purine nucleoside phosphorylase deficiency. *J Pediatr Hematol Oncol* 2002;24:69-71.
5. Stoo JW, Zegers BJM, Hendrickx GFM, et al: Purine nucleoside phosphorylase deficiency associated with selective cellular immunodeficiency. *N Engl J Med* 1977;296:651-655.
6. Rich KC, Arnold WJ, Palella T, Fox IH: Cellular immune deficiency with autoimmune hemolytic anemia in purine nucleoside phosphorylase deficiency. *Am J Med* 1979;67:172-176.
7. Watson AR, Evans DIK, Marsden HB, et al: Purine nucleoside phosphorylase deficiency associated with a fatal lymphoproliferative disorder. *Arch Dis Child* 1981;56:563-565.
8. Soutar RL, Day RE: Dysequilibrium/ataxic diplegia with immunodeficiency. *Arch Dis Child* 1991;66:982-983.
9. Hagberg B, Hansson O, Liden S, Nilsson K: Familial ataxic diplegia with deficient cellular immunity. A new clinical entity. *Acta Paediatr Scand* 1970;59:545-550.
10. Graham-Pole J, Gibson AAM, Stephenson JBP: Familial dysequilibrium-diplegia with T lymphocyte deficiency. *Arch Dis Child* 1975;50:927-933.
11. Markert ML, Finkel BD, McLaughlin TM, et al: Mutations in purine nucleoside phosphorylase deficiency. *Hum Mutat* 1997;9:118-121.
12. Broome CB, Graham ML, Saulsbury FT, et al: Correction of purine nucleoside phosphorylase deficiency by transplantation of allogeneic bone marrow from a sibling. *J Pediatr* 1996;128:373-376.