

Review

QJM

Clinical and immunological aspects of HLA class I deficiency

J. ZIMMER¹, E. ANDRÈS², L. DONATO³, D. HANAU⁴,
F. HENTGES¹ and H. DE LA SALLE⁴

From the ¹Laboratoire d'Immunogénétique-Allergologie, Centre de Recherche Public de la Santé (CRP-Santé), Luxembourg, ²Service de Médecine Interne, Clinique Médicale B, and ³Service de Pédiatrie, Hôpitaux Universitaires de Strasbourg, Strasbourg, France, and ⁴INSERM E 0345, Etablissement Français du Sang-Alsace, Strasbourg, France

Summary

Human leukocyte antigen (HLA) class I deficiency is a rare disease with remarkable clinical and biological heterogeneity. The spectrum of possible manifestations extends from the complete absence of symptoms to life-threatening disease conditions. It is usually diagnosed when HLA class I serological typing is unsuccessful; flow cytometric studies then reveal a severe reduction in the cell surface expression of HLA class I molecules (90–99% reduction compared to normal cells). In most cases to date, this low expression is due to a homozygous inactivating mutation in one of the two subunits of the transporter associated with antigen processing (TAP), critically involved in the peptide loading of HLA class I molecules. Although asymptomatic cases have been described,

TAP deficiencies are usually characterized by chronic bacterial infections of the upper and lower airways, evolving to bronchiectasis, and in half of the cases, also skin ulcers with features of a chronic granulomatous inflammation. Despite the defect in HLA class-I-mediated presentation of viral antigens to cytotoxic T cells, the patients do not suffer from severe viral infections, presumably because of other efficient antiviral defence mechanisms such as antibodies, non-HLA-class-I-restricted cytotoxic effector cells and CD8⁺ T-cell responses to TAP-independent antigens. Treatment is at present exclusively symptomatic, and should particularly focus on the prevention of bronchiectasis, which requires early detection.

Introduction

Although few in number, several patients with reduced cell surface expression of HLA class I molecules have been reported in recent years, and most have one of a set of characteristic clinical pictures. Isolated HLA class I deficiency, also termed 'type I bare lymphocyte syndrome' (type I BLS), is not usually life-threatening, in contrast to the more severe HLA class II deficiency (type II BLS) and

combined HLA class I and II deficiencies. The symptoms present in the majority of the patients are rather unexpected, considering the role of HLA class I molecules in the presentation of viral peptides to cytotoxic T lymphocytes. In this review, we summarize the mechanisms of HLA-class-I-mediated antigen presentation, and then describe the different subtypes of HLA class I deficiency

Address correspondence to Dr J. Zimmer, Laboratoire d'Immunogénétique-Allergologie, CRP-Santé, 84 Val Fleuri, L-1526 Luxembourg. email: jacques.zimmer@crp-sante.lu

© The Author 2005. Published by Oxford University Press on behalf of the Association of Physicians. All rights reserved. For Permissions, please email: journals.permissions@oxfordjournals.org

known to date, with their corresponding clinical pictures. We then present the immunological features found in the patients, the differential diagnosis and treatment modalities, and finally propose a pathophysiological model that may explain the observed symptoms.

HLA class I molecules and antigen presentation

HLA class I molecules are expressed at the surface of all nucleated human cells. They are composed of a heavy chain encoded by HLA class I genes, a light chain called β_2 -microglobulin (β_2m), and a peptide 8–10 amino acids in length, derived from the proteolysis in the cytosol of endogenous proteins. These smaller peptides are presented by the HLA class I molecules to cytotoxic $CD8^+$ T lymphocytes, and thus, HLA class I molecules reflect at the cell surface the genes expressed by the cell. The presentation of antigenic peptides by dendritic cells (particularly in the case of a viral infection) induces the proliferation and activation of $CD8^+$ T cells, which become cytotoxic towards infected cells that also express the same HLA class I/peptide complexes on their cell surface.^{1–5}

HLA class I heavy chains are encoded by genes located on chromosome 6 within the HLA complex, which also contains the genes of HLA class II and class III molecules, as well as many other genes whose products are implicated in antigen presentation, inflammation and activation of the immune system. Three extremely polymorphic loci encode the so-called classical HLA class I molecules: HLA-A, HLA-B and HLA-C. As each allele of these loci is co-dominantly expressed, most individuals express up to six different HLA class I molecules, with a different repertoire of preferentially presented peptides for each of them.^{1,3,6}

Cytosolic proteins are degraded by a large multimeric proteolytic complex, the proteasome, although other proteases may also play a role (Figure 1). The peptides that result from this process are translocated into the lumen of the endoplasmic reticulum (ER) by TAP. This molecule is a heterodimer inserted in the membrane of the ER, composed of two subunits, TAP1 and TAP2, whose genes are located in the HLA class II region of the HLA complex. It is a member of the ATP-binding cassette family of transport proteins.^{1–5} Both subunits are required for efficient peptide transport, although TAP1 homodimers have been reported to be functional for some particular peptides.^{3,7}

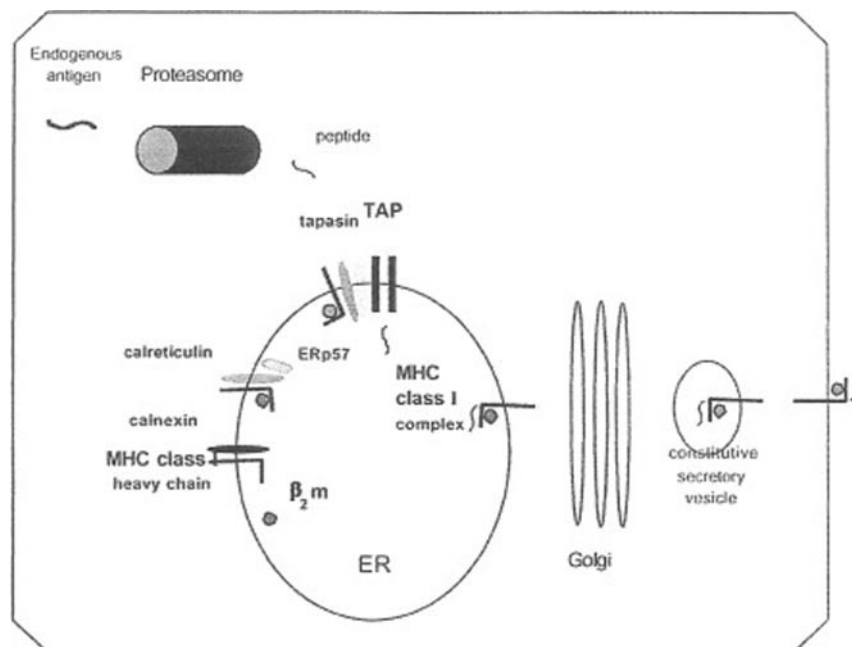


Figure 1. Schematic model of the conventional MHC class I antigen processing and presentation pathway. Endogenous antigens are degraded by the proteasome into short peptides. These peptides are transported into the ER lumen by TAP. In the ER, newly-synthesized MHC class I heavy chains assemble with β_2m and peptide. This assembly process involves transient interactions with calnexin, calreticulin, Erp57, tapasin and TAP. Upon peptide binding, the MHC class I heterotrimeric complex is released from the ER and transported to the cell surface via the constitutive secretory pathway. Reprinted from reference 1, with permission from Elsevier.

Newly synthesized HLA class I heavy chains enter the ER and then bind to BiP and calnexin. The association with these chaperones precedes and facilitates the association with $\beta 2m$. Subsequently, the heavy chain/ $\beta 2m$ complex detaches from calnexin to bind to other chaperones, calreticulin and Erp57, before it can interact with TAP (Figure 1).^{1–5} The binding to TAP is mediated by tapasin (TAP-associated glycoprotein), yet another chaperone molecule, whose gene is located near the TAP genes within the HLA complex. Tapasin forms a bridge between TAP and heavy chains and, in a peptide-loading complex, enhances peptide loading.^{1,8} Peptide acquisition stabilizes HLA class I molecules, which can then leave the ER and be expressed at the cell surface, whereas they are rapidly degraded in the absence of peptide,^{1–3} as occurs (for example) if TAP is not functional.

Subtypes of HLA class I deficiency

Symptomatic TAP deficiency

The patients have a very large (30- to 100-fold) reduction in the cell surface expression levels of HLA class I molecules, compared to normal donors. They display recurrent bacterial infections of the

respiratory tract, and about half of them also have granulomatous skin lesions. Patients generally reach adult age, however. Their HLA genotype is homozygous and their parents are usually first cousins.^{9,10} To date, 14 patients have been described in the literature^{9–21} and are listed in Table 1. Five of them have a TAP1 deficiency and eight a TAP2 deficiency. In the last case,²² the cause of the defect has not been investigated but the clinical picture is identical to that observed in the others. Furthermore, two of the patients had brothers with exactly the same symptoms who died at the age of 20 and 22 years, respectively.^{17,20}

Severe viral infections do not occur. In contrast, after a latency period of about 4–7 years without major health problems, patients begin to present with recurrent and rapidly chronic bacterial infections of the upper respiratory tract (purulent rhinitis, pansinusitis, otitis media). Nasal polyps are frequent. A few years later, the infections extend to the lower respiratory tract (bronchitis, bronchiolitis, bacterial pneumonia, bronchiectasis). Pathogens usually identified are *Haemophilus influenzae*, *Streptococcus pneumoniae*, *Staphylococcus aureus*, *Klebsiella* spp., *Escherichia coli* and *Pseudomonas aeruginosa*. The chronic bacterial infections and the bronchiectasis may progressively lead to respiratory failure and death.^{9–20,22}

Table 1 Summarized data on all currently described HLA class I deficiencies

Patient	Sex	Symptoms	Age at onset (years)	Family	Parents	HLA genotype	Defect	References
1	M	Anaemia	9	1	Unrelated	Heterozygous	Transcription?	9, 10, 23
2	M	None	NA	1	Unrelated	Heterozygous	Transcription?	9, 10, 23
3	M	None	NA	2	Unrelated	Heterozygous	Transcription?	9
4	F	R	4	3	First cousins	Homozygous	TAP2	9, 11–13
5	M	R	7	3	First cousins	Homozygous	TAP2	9, 11–13
6	F	R+C	R 15, C 28	4	First cousins	Homozygous	TAP1	14–16
7	M	R+C	R c/h, C 8	5	First cousins	Homozygous	TAP1	14, 17
8	F	R+C	R c/h, C 25	6	*	Homozygous	TAP2	10, 18, 19
9	F	R+C	R c/h, C 20	6	*	Homozygous	TAP2	10, 18
10	F	R+C	R c/h, C 15	7	*	Homozygous	TAP1	10, 18
11	F	R+C	R c/h, C 20	8	*	Homozygous	TAP1	10, 18
12	F	C	3	9	*	Homozygous	TAP1	10, 18
13	M	R	c/h	10	First cousins	Homozygous	TAP2	20, 28
14	F	R	c/h	11	First cousins	Homozygous	TAP2	21
15	M	R	c/h	11	First cousins	Homozygous	TAP2	21
16	M	R	c/h	11	First cousins	Homozygous	TAP2	21
17	M	R	c/h	12	First cousins	Unknown	Unknown	22
18	M	Transient C	43	13	Uncle/niece	Homozygous	TAP2	24
19	F	None	NA	13	Uncle/niece	Homozygous	TAP2	24
20	F	None	NA	14	Unrelated	Homozygous	Tapasin	8

Where the same number appears in the 'Family' column, patients belong to the same family (i.e. siblings). R, respiratory; C, cutaneous; c/h, childhood; NA, not applicable. *No information available about the parents.

Cutaneous manifestations may start either in childhood (two cases) or at adult age (five cases) and have been observed in seven patients.^{9,10,16–18} They are necrotizing granulomatous lesions that develop from a small pustule or subcutaneous nodule, with progressive extension and ulceration. They are most often asymmetrically distributed over the legs,^{10,18} but also involved the hands in one patient.¹⁷ Healing is very slow, and may evolve to hyperpigmented scars. Four patients developed facial lesions that predominate around and on the nose where they may be extremely mutilating, with septal perforation and complete destruction of the nasal cartilage, resembling lethal midline granuloma. One of the patients with skin involvement had no recurrent respiratory infections.^{10,18}

Necrotizing granulomatous inflammation can be identified in skin and upper airway biopsies, but not in the lungs of the TAP-deficient patients.¹⁰

Infections of the central nervous system (encephalomyelitis, cerebral abscess) occurred in two patients mistakenly treated with immunosuppressive drugs for suspected Wegener's granulomatosis,¹⁰ as well as in another patient's brother, who presumably also had a TAP deficiency.¹⁷ Two patients developed simultaneous polyarthritis and leukocytoclastic skin vasculitis, which were considered hypersensitivity vasculitis secondary either to chronic infections or to drugs.¹⁰

Of the patients currently known, two died in a context of respiratory failure at the ages of 36¹⁸ and 23¹⁷ years, respectively.

Atypical HLA class I deficiencies

In this category, the reduction in surface expression of HLA class I molecules is less pronounced (approximately 10-fold).^{9,10} Very heterogeneous in terms of the molecular origins, the defect may be considered as atypical because it is characterized by the absence of clinical symptoms or, in two instances, by only transient and moderate ones. Six cases have been described to date,^{8,9,10,23} and are presented in Table 1.

The first subgroup comprises three individuals^{9,10,23} (two are siblings²³) with heterozygous HLA genotypes and non-consanguineous parents. The amount of messenger RNA of HLA class I and $\beta 2m$ is reduced, suggesting defective transcription of these genes.^{9,10} On EBV-transformed B lymphocytes from these patients, the surface expression of HLA class I molecules progressively increases within a few weeks of culture, whereas it can be induced on activated T cells and further up-regulated by TNF- α , IFN- α or IFN- γ to the levels observed on resting cells from normal

individuals.^{9,23} Thus, HLA class I genes may be sufficiently up-regulated by inflammatory cytokines ('conditional' deficiency) to explain the benign clinical course.⁹ However, the three individuals were described in childhood, at a time where symptoms may not yet have developed, and long term follow-up data are not available. In addition, one of the siblings presented with unexplained anaemia that recovered under corticosteroid treatment.²³

Two further cases are adult siblings born to consanguineous parents (uncle and niece).²⁴ They have a homozygous HLA genotype and evidence of a TAP2 deficiency. The reduction in surface expression of HLA class I molecules compared to normal donors is approximately 10-fold. Thus, TAP deficiencies may lead to variably severe reductions in the surface levels of HLA class I molecules. The brother was 46 years old at diagnosis, and suffered at that time from intracranial hypertension due to a congenital cyst of the septum pelucidum, treated by a ventriculo-peritoneal shunt. Since the age of 43, he had a limited chronic eruption on one leg consisting of erythematous and brownish confluent lupoid papules and plaques that disappeared one year after the discovery of the TAP deficiency. His sister was 30 years old and completely asymptomatic, her HLA class I deficiency being detected during family screening.²⁴ None of the siblings had the characteristic respiratory problems usually observed in TAP-deficient patients.

Finally, an asymptomatic tapasin deficiency has been described in a 54-year-old woman.⁸ She suffered from a primary chronic glomerulonephritis, and had a history of herpes zoster infection and polyps of the stomach and colon, but no respiratory or cutaneous manifestations of HLA class I deficiency. Her defect was discovered during serological HLA typing prior to kidney transplantation. Although not born of consanguineous parents, she nevertheless had a homozygous HLA genotype.

Combined HLA class I and II deficiency

In this situation, a significant reduction in the surface expression of HLA class I molecules is associated with a lack of expression of HLA class II molecules.^{9,25,26} As in type II BLS, the resulting absence of humoral and cellular immune responses produces extreme susceptibility to viral, bacterial and parasitic infections early in life. The reduced expression of HLA class I molecules seems to be a direct consequence of the mutations of the RFX complex, which regulates the transcription of HLA

class II genes. Indeed, the promoters of the genes of the heavy chains of HLA class I molecules, and of $\beta 2m$, contain binding motifs for several subunits of the RFX complex. These transcription factors thus may also play a role in the transactivation of the genes of HLA class I molecules.

Strategies for biological diagnosis

Although patient history and clinical picture may strongly suggest HLA class I deficiency, diagnosis needs to be confirmed by serological HLA typing (but not by molecular HLA typing because this would not identify the disease) and/or by flow cytometry (staining of PBMC by a pan-anti-HLA-class-I antibody such as W6/32). Cells from parents and siblings should be included, in order to identify other affected family members. The degree to which surface expression of HLA class I molecules is reduced may already give some indications about the possible origin of the defect. HLA genotyping of the patient and his family should be performed. If the patient's HLA genotype is homozygous, the deficiency is likely to be linked to chromosome 6, and may thus be a TAP or a tapasin deficiency whose transmission is recessive and autosomal. If not, a transcriptional and conditional defect could be envisaged, and confirmed by activation of T cells (PHA, IL-2, allogeneic feeder cells) and further stimulation with inflammatory cytokines, which should then strongly up-regulate HLA class I molecules.⁹

If no significant up-regulation occurs under these conditions, intracellular HLA class I molecules may be studied by biochemical approaches (pulse-chase metabolic labelling with ³⁵S, immunoprecipitation with an anti-HLA-class-I antibody, endoglycosidase H treatment of the immunoprecipitates and separation by SDS polyacrylamide gel electrophoresis). This will indicate whether: (i) the neosynthesis of HLA class I heavy chains is affected; (ii) they associate with $\beta 2m$; and (iii) they are sialylated (as revealed by a remaining endoglycosidase H-sensitivity). A defect in peptide loading, and in particular a TAP deficiency, can be deduced from the absence of conversion of HLA class I heavy chains into endoglycosidase-H-resistant forms. Indeed, empty HLA class I molecules cannot reach the Golgi apparatus to be sialylated, as they remain in the ER and are unstable.⁹

When EBV-transformed B lymphoblastoid cell lines from the patients are available, they can be used for infection with recombinant vaccinia viruses expressing TAP1, TAP2 or both subunits. Flow cytometry analysis of HLA class I expression of cells infected with these different viruses can

show whether there is a TAP deficiency and if so, which subunit is mutated.^{9,14,24} Another option is to detect the absence of TAP1, TAP2 or tapasin proteins by Western blot.^{8,18,20} Finally, the exact nature of the underlying mutation may be identified by gene sequencing.

Biological findings

TAP deficiency has been molecularly characterized in nine cases^{11,14,18,20,24} by the identification of a point mutation (two in the TAP1 gene, seven in the TAP2 gene) leading to a premature stop codon, with or without frameshift, and thus to a truncated and non-functional protein. The asymptomatic TAP-deficient siblings have a mutation in the gene region encoding the ATP-binding cassette that destroys the activity of TAP2, although interactions with TAP1 and tapasin should be preserved.²⁴ Although all known mutations are, with the exception of intrafamilial cases, located at different sites of the sequence, a limited number of different mutations may exist, as suggested by recurrent HLA haplotypes that may carry the same mutation. Indeed, two unrelated TAP1-deficient patients^{14,18} have the same HLA genotype, and both display cutaneous lesions. On the other hand, some TAP2-deficient patients from Israel²¹ and from Lebanon²⁴ share the same HLA haplotype, but the former are severely affected, whereas the latter are asymptomatic. There is at present no explanation for this discrepancy, as both families live in more or less the same geographic area.

The affected subunit was determined in six patients either by Western blot¹⁸ or by a cell fusion technique²¹. In the tapasin-deficient patient, the tapasin gene carries a large deletion and encodes a frameshifted, truncated polypeptide⁸.

If the absolute lymphocyte number in peripheral blood is usually normal, the proportion of T cells may be moderately reduced.^{9,27} In one patient, a progressive decline of CD4⁺ and CD8⁺ T lymphocytes was observed,¹⁷ whereas another one was lymphopenic.²⁰ Percentages of CD8⁺ T cells (normally around 30% of all T lymphocytes) vary from more or less severe reductions (7–20%) to normal or even elevated values (88% of PBMC in one patient).^{9,11,12,17,18,27} Repeated investigations may reveal very different values in the same patient.

In most cases however, the percentage of TCR $\alpha\beta$ ⁺ T cells among the CD8⁺ population was not analysed, although it is precisely this subtype that should be affected by the TAP deficiency, because it is positively selected in the thymus by HLA class I molecules.^{9,11} At least in the two

symptomatic patients that we have studied in detail,⁹ a high proportion (30–45%) of TCR $\gamma\delta^+$ T cells are CD8⁺. TCR $\gamma\delta^+$ T cells are expanded in these patients, and their proportion increases with age, so the simple determination of CD8⁺ T cell numbers may lead to an overestimation of the proportion of TCR $\alpha\beta^+$ CD8⁺ T lymphocytes. An expansion of TCR $\gamma\delta^+$ T cells has been described in several other cases,^{18,20,24} including one of the asymptomatic TAP-deficient patients (who otherwise had a normal T lymphocyte subset distribution, similar to his sister and his parents).²⁴ In contrast to normal donors, whose peripheral blood $\gamma\delta$ T cells are predominantly of the V δ 2 type, the repertoire is skewed toward V δ 1 in all the TAP-deficient patients who have been analysed for this.^{19,20,28} The percentages of NK cells are variable, but within normal values.^{9,11,18,27}

The absence of a coherent pattern of distribution of several T lymphocyte subsets (with the remarkable exception of the frequently expanded TCR $\gamma\delta^+$ fraction) probably reflects more the age differences between the patients and their past and present infections, rather than any direct consequence of the TAP deficiency. In any case, even the low levels of HLA class I molecules seem to be sufficient to select significant numbers of TCR $\alpha\beta^+$ T cells, and in the asymptomatic patients, the less severe reduction of HLA class I levels has no apparent consequences for this process.²⁴ In addition, in some patients, TCR $\alpha\beta^+$ CD8⁺ T cell clones recognizing TAP-independent viral antigens could be isolated.^{9,10,24,29}

High or normal titres of antibodies towards common viruses (measles, mumps, influenza, herpes, varicella, EBV, CMV) are present in patients' sera.^{9,12,17,18} Immunoglobulin (Ig) levels and different Ig subclasses are usually normal or increased,^{9,12,16,18,22} except in two cases with low concentrations of IgG2,^{17,20} one of them also presenting with an absence of IgG4.¹⁷ TAP-deficient patients display normal delayed cutaneous hypersensitivity, and their PBMC respond normally or sub-normally to mitogens and alloantigens.^{9,12,16,17,22}

Functional tests on peripheral blood NK cells (which preferentially kill target cells with low expression of HLA class I molecules) from these patients revealed that they have no cytotoxic activity towards class-I-deficient targets,^{27,30} unlike NK cells from normal donors. Upon cytokine-mediated activation, however, they rapidly acquire cytotoxic activity, and become able to destroy not only tumour or EBV-transformed cells (including autologous EBV-transformed B lymphoblastoid cell lines),^{18,30} but also normal autologous cells such

as skin fibroblasts,³¹ while autologous T cell blasts are spared.³² The repertoire of activating and inhibitory NK cell receptors is normal in these patients.^{30,32} Destruction of autologous cells by TAP-deficient TCR $\gamma\delta^+$ T cells has likewise been reported.¹⁸

Differential diagnosis

This aspect has been extensively reviewed by Gadola, *et al.*¹⁰ Careful clinical and biological investigations should allow the discrimination of TAP deficiency from other disease conditions matching part of the respiratory and/or cutaneous symptomatology, such as chronic granulomatous disease, common variable immunodeficiency, lethal midline granuloma, Wegener's granulomatosis, sarcoidosis, mycobacterial infections, cystic fibrosis and primary ciliary dyskinesia.¹⁰

Treatment

A curative treatment of TAP deficiency is not yet available, but some approaches can at least be discussed. Gene therapy might be technically impossible, as HLA class I molecules are widely expressed on nucleated cells.¹⁰ Lung transplantation could be an option,¹⁰ if it can be shown that damage to patients' pulmonary and bronchial tissues is indeed predominantly due to autoreactive NK and TCR $\gamma\delta^+$ T cells (which would be inhibited by the HLA class I molecules expressed by the graft). As regards bone-marrow transplantation, it would lead to the establishment of a HLA class-I-positive haematopoietic system in a HLA class-I-deficient environment, with a risk of severe graft-versus-host disease mediated by donor NK cells.¹⁰ However, studies in mice have demonstrated that normal NK cells developing in a MHC class-I-negative environment become tolerant to MHC class-I-deficient cells.³³ But further pathophysiological studies would be needed before such treatments could be considered.

The following treatment recommendations are not based on evidence obtained from large-scale clinical trials; these are impossible, due to the low number of patients. Nevertheless, some of them have (for example) been applied on an empirical basis to the first two TAP-deficient patients described,^{11–13} and led to a stabilization of the respiratory pathology and a clinical improvement (unpublished data). When diagnosis is made in infancy, for instance in the case of early detection in the family of a known patient, nurseries and other infant communities should be avoided to reduce

the risk of early viral contamination.⁹ Vaccinations against respiratory pathogens should be performed and exposure to tobacco smoke avoided.⁹ Once installed, the respiratory pathology should benefit from treatment modalities similar to that of cystic fibrosis,¹⁰ consisting of antibiotic therapy of bacterial infections,^{9,10} if necessary by intravenous administration,⁹ and chest physiotherapy.¹⁰ This approach should delay the appearance of bronchiectasis. Erythromycin was reported to be efficient in one case.³⁴ Intravenous Ig in addition to antibiotics seems to be beneficial in some patients.¹⁰ Surgery in the context of chronic sinusitis is not recommended, because it is not only inefficient but also appears to worsen nasal pathology and bronchial infections (postnasal drip syndrome).¹⁰ However, this was not confirmed in one patient.³⁴

Cutaneous lesions should benefit from a local treatment aiming at promoting healing and reducing bacterial colonization. Psoralen and UVA were transiently efficient in two patients.¹⁰

Immunomodulatory treatment with IFN- α (two patients) and IFN- γ (one patient) led to progression of the skin lesions and severe side-effects,¹⁰ and should thus be avoided. Even worse was the effect of immunosuppressive therapy, consisting of steroids in combination with either cyclophosphamide, methotrexate, azathioprine or cyclosporine.¹⁰ The two patients receiving this treatment experienced progression of both skin lesions and pulmonary disease, and infections of the nervous system.¹⁰ Although it may be tempting for clinicians to introduce immunosuppressive drugs to control the granulomatous lesions, this type of therapy is strongly contraindicated in TAP-deficient patients.

Physiopathology

In symptomatic TAP deficiency, the absence of severe viral infections despite the defective presentation of viral antigens to CD8⁺ T lymphocytes may be explained, at least in part, by different factors: (i) normal humoral response, (ii) presence of significant, although frequently reduced, numbers of TCR $\alpha\beta$ ⁺ CD8⁺ T cells, (iii) recognition by certain TCR $\alpha\beta$ ⁺ CD8⁺ T cells of TAP-independent viral antigens, (iv) expansion of TCR $\gamma\delta$ ⁺ T cells and finally (v) presence of NK cells, the latter two lymphocyte subsets eliminating virally infected cells without the need for a class-I-mediated antigen presentation.^{9–11,15,18,19,24,27,29}

However, these various defence mechanisms would not be enough to clear the viral infections rapidly and completely. Some viruses induce the production of IL-8, which recruits neutrophils and

T lymphocytes to the infectious site. Upper and lower airways would thus on the one hand be attacked by viruses inefficiently eliminated by the immune system and, on the other hand, by the proteolytic enzymes released by the high numbers of neutrophils. The various cytokines and chemokines produced during this response may further attract and activate NK cells and TCR $\gamma\delta$ ⁺ T cells, which could then contribute to the immune defence, but would also lyse uninfected bystander cells expressing insufficient amounts of HLA class I molecules to inhibit these activated cytotoxic effectors. Together, these processes may progressively lead to chronic epithelial alterations and tissue remodelling that could favour the development of bacterial infections. Those would in turn worsen the situation by stimulating further recruitment of neutrophils, macrophages and lymphocytes, and the development of a chronic inflammatory state.⁹ This view is supported by the observation that erythromycin, an antibiotic that also inhibits neutrophil function³⁵ and accumulation,³⁶ seems to be beneficial in the treatment of TAP-deficiency-associated lung disease.³⁴ On the other hand, Schultz, *et al.*³⁷ showed that TAP-deficient patients frequently have ANCA (anti-neutrophil cytoplasmic auto-antibodies) against the neutrophil antibacterial molecule BPI (bactericidal/permeability-increasing protein), so that bacterial clearance would be reduced due to the inactivation of BPI by auto-antibodies.

The predominance and chronic evolution of bacterial infections in TAP-deficient patients suggests that in the airways, presentation of bacterial, exogenous antigens by HLA class I molecules to CD8⁺ T cells (cross-presentation) might be important,^{11,38} although this point has not yet been addressed experimentally. TAP-dependent as well as TAP-independent non-classical pathways of MHC class-I-mediated presentation of exogenous antigens have been described,^{1,2,4,5} the latter being relatively inefficient, at least in murine macrophages.³⁹ In this context, it is very interesting to consider the recent description⁴⁰ of a 25-year-old patient from a consanguineous family, who has suffered since childhood from recurrent otitis media and bronchitis, and presented with disseminated bronchiectasis. Although his symptoms perfectly matched those observed in TAP-deficiency, his expression of HLA class I molecules was normal, as were Ig levels and IgG subclasses. Instead, a total absence of CD8⁺ cells was found, due to a homozygous missense mutation in the CD8 α gene. Based on this observation and on those made in TAP-deficient patients, more precise investigations of the exact role and importance of CD8⁺ T cells in antibacterial defence might be useful.

The origin of the skin ulcers found in some TAP-deficient patients is not completely clear. When administered, tuberculostatic treatments had no effect. Mycobacteria, leishmania, fungi or other pathogens have never been identified in these lesions, although different techniques, including PCR, have been used.^{10,17,18} Skin biopsies revealed an infiltration of macrophages¹⁷ and lymphocytes^{17,18} in the dermis. Interestingly, a high percentage of these lymphocytes were NK cells; TCR $\gamma\delta^+$ T cells were also present, but to a lesser extent.¹⁸ Thus, the two types of cytotoxic effectors that have been shown *in vitro* to kill autologous HLA class-I-deficient target cells can indeed be found in lesional tissue. It is conceivable that in the skin, local viral or bacterial infections stimulate the influx of T lymphocytes and activated NK cells, which would again be insufficiently inhibited by autologous HLA class I molecules and be at the origin of autoimmune processes. Production of cytokines like IFN- γ by NK cells would further strengthen these phenomena by inducing a Th1 lymphocyte response.^{10,18}

Concluding remarks

Since the first description of TAP-deficient patients 11 years ago,¹¹ several groups have reported additional cases of this deficiency. Although the number of known patients is rising, it will probably (and fortunately) remain low, due to its autosomal recessive transmission. Nevertheless, clinicians should be aware of this disease and the relatively simple methods to diagnose it biologically. From a more theoretical point of view, the absence of severe viral infections is somewhat intriguing, as are the characteristics of the symptoms observed, and those should lead to a fresh look at some aspects of antigen presentation and immune defense mechanisms.

References

- Grommé M, Neefjes J. Antigen degradation or presentation by MHC class I molecules via classical and non-classical pathways. *Mol Immunol* 2002; **39**:181–202.
- Pamer E, Cresswell P. Mechanisms of MHC class I-restricted antigen processing. *Annu Rev Immunol* 1998; **16**:323–58.
- York IA, Rock KL. Antigen processing and presentation by the class I major histocompatibility complex. *Annu Rev Immunol* 1996; **14**:369–96.
- Watts C, Powis S. Pathways of antigen processing and presentation. *Rev Immunogenetics* 1999; **1**:60–74.
- Yewdell JW, Norbury CC, Bennink JR. Mechanisms of exogenous antigen presentation by MHC class I molecules

in vitro and *in vivo*: implications for generating CD8⁺ T cell responses to infectious agents, tumors, transplants, and vaccines. *Adv Immunol* 1999; **73**:1–77.

- The MHC sequencing consortium. Complete sequence and gene map of a human major histocompatibility complex. *Nature* 1999; **401**:921–3.
- Gabathuler R, Reith G, Kolaitis G, et al. Comparison of cell lines deficient in antigen presentation reveals a functional role for TAP-1 alone in antigen processing. *J Exp Med* 1994; **180**:1415–25.
- Yabe T, Kawamura S, Sato M, et al. A subject with a novel type I bare lymphocyte syndrome has tapasin deficiency due to a deletion of 4 exons by Alu-mediated recombination. *Blood* 2002; **100**:1496–8.
- De la Salle H, Donato L, Zimmer J, et al. HLA class I deficiencies. In: Ochs HD, Smith CIE, Puck JM, eds. *Primary Immunodeficiency Diseases: a molecular and genetic approach*. New York, Oxford University Press, 1999:181–8.
- Gadola SD, Moins-Teisserenc HT, Trowsdale J, et al. TAP deficiency syndrome. *Clin Exp Immunol* 2000; **121**:173–8.
- De la Salle H, Hanau D, Fricker D, et al. Homozygous human TAP peptide transporter mutation in HLA class I deficiency. *Science* 1994; **265**:237–41.
- Donato L, de la Salle H, Hanau D, et al. Association of HLA class I antigen deficiency related to a TAP2 gene mutation with familial bronchiectasis. *J Pediatr* 1995; **127**:895–900.
- Donato L, de la Salle H, Hanau D, et al. Déficit en antigènes HLA de classe I et bronchiectasies familiales: revue de la littérature avec étude clinique et biologique. *Rev Fr Allergol* 1997; **37**:127–34.
- De la Salle H, Zimmer J, Fricker D, et al. HLA class I deficiencies due to mutations in subunit 1 of the peptide transporter TAP1. *J Clin Invest* 1999; **103**:R9–13.
- Furukawa H, Murata S, Yabe T, et al. Splice acceptor site mutation of the transporter associated with antigen processing-1 gene in human bare lymphocyte syndrome. *J Clin Invest* 1999; **103**:755–8.
- Maeda H, Hirata R, Chen RF, et al. Defective expression of HLA class I antigens: a case of the bare lymphocyte syndrome without immunodeficiency. *Immunogenetics* 1985; **21**:549–58.
- Plebani A, Monafo V, Cattaneo R, et al. Defective expression of HLA class I and CD1a molecules in boy with Marfan-like phenotype and deep skin ulcers. *J Am Acad Dermatol* 1996; **35**:814–18.
- Moins-Teisserenc HT, Gadola SD, Cella M, et al. Association of a syndrome resembling Wegener's granulomatosis with low surface expression of HLA class I-molecules. *Lancet* 1999; **354**:1598–603.
- Teisserenc H, Schmitt W, Blake N, et al. A case of primary immunodeficiency due to a defect of the major histocompatibility gene complex class I processing and presentation pathway. *Immunol Lett* 1997; **57**:183–7.
- Matamoros N, Milà J, Llano M, et al. Molecular studies and NK cell function of a new case of TAP2 homozygous human deficiency. *Clin Exp Immunol* 2001; **125**:274–82.
- Markel G, Mussafi H, Ling KL, et al. The mechanisms controlling NK cell autoreactivity in TAP2-deficient patients. *Blood* 2004; **103**:1770–8.
- Sugiyama Y, Maeda H, Okumura K, Takaku F. Progressive sinobronchiectasis associated with the 'Bare Lymphocyte Syndrome' in an adult. *Chest* 1986; **89**:398–401.

23. Payne R, Brodsky F, Peterlin BM, Young LM. Bare lymphocytes without immunodeficiency. *Hum Immunol* 1983; **6**:219–27.
24. De la Salle H, Saulquin X, Mansour I, et al. Asymptomatic deficiency in the peptide transporter associated to antigen processing. *Clin Exp Immunol* 2002; **128**:525–31.
25. Mach B, Steimle V, Martinez-Soria E, Reith W. Regulation of MHC class II genes: lessons from a disease. *Annu Rev Immunol* 1996; **14**:301–31.
26. Gobin SJ, Peijnenburg A, van Eggermond M, et al. The RFX complex is crucial for the constitutive and CIITA-mediated transactivation of MHC class I and β 2-microglobulin genes. *Immunity* 1998; **9**:531–41.
27. Furukawa H, Yabe T, Watanabe K, et al. Tolerance of NK and LAK activity for HLA class I-deficient targets in a TAP1-deficient patient (bare lymphocyte syndrome type I). *Hum Immunol* 1999; **60**:32–40.
28. Crespi C, Julià MR, Munoz-Saa I, et al. Skewed inhibitory receptors expression in a TAP2-deficient patient. *Immunol Lett* 2003; **68**:149–53.
29. De la Salle H, Houssaint E, Peyrat MA, et al. Human peptide transporter deficiency. Importance of HLA-B in the presentation of TAP-independent EBV antigens. *J Immunol* 1997; **158**:4555–63.
30. Zimmer J, Donato L, Hanau D, et al. Activity and phenotype of natural killer cells in peptide transporter (TAP)-deficient patients (type I bare lymphocyte syndrome). *J Exp Med* 1998; **187**:117–22.
31. Zimmer J, Donato L, Hanau D, et al. Inefficient protection of human TAP-deficient fibroblasts from autologous NK cell-mediated lysis by cytokines inducing HLA class I expression. *Eur J Immunol* 1999; **29**:1286–91.
32. Vitale M, Zimmer J, Castriconi R, et al. Analysis of natural killer cells in TAP2-deficient patients: expression of functional triggering receptors and evidence for the presence of inhibitory receptor(s) that prevent lysis of normal autologous cells. *Blood* 2002; **99**:1723–9.
33. Wu MF, Raulet DH. Class I-deficient hemopoietic cells and nonhemopoietic cells dominantly induce unresponsiveness of natural killer cells to class I-deficient bone marrow cell grafts. *J Immunol* 1997; **158**:1628–33.
34. Azuma A, Keicho N, Furukawa H, et al. Prolonged survival of a bare lymphocyte syndrome type I patient with diffuse panbronchiolitis treated with erythromycin. *Sarcoidosis Vasc Diffuse Lung Dis* 2001; **18**:312–13.
35. Sugihara E, Koyanagi T, Niizeki T, et al. Macrolide antibiotics directly reduce active oxygen generation by neutrophils in human peripheral blood. *Kurume Med J* 2003; **50**:9–15.
36. Keicho N, Kudoh S. Diffuse panbronchiolitis: role of macrolides in therapy. *Am J Respir Med* 2002; **1**:119–31.
37. Schultz H, Schinke S, Weiss J, et al. BPI-ANCA in transporter associated with antigen presentation (TAP) deficiency: possible role in susceptibility to Gram-negative bacterial infections. *Clin Exp Immunol* 2003; **133**:252–9.
38. Raghavan M. Immunodeficiency due to a defective antigen processing: the molecular basis for type 1 bare lymphocyte syndrome. *J Clin Invest* 1999; **103**:595–6.
39. Campbell DJ, Serwold T, Shastri N. Bacterial proteins can be processed by macrophages in a transporter associated with antigen processing-independent, cysteine protease-dependent manner for presentation by MHC class I molecules. *J Immunol* 2000; **164**:168–75.
40. De la Calle-Martin O, Hernandez M, Ordi J, et al. Familial CD8 deficiency due to a mutation in the CD8 α gene. *J Clin Invest* 2001; **108**:117–23.